Cardiomyopathy as an initial presentation of Hereditary Transthyretin Amyloidosis caused by mutation Val50Met a case report

Giliberto C[1], Pradotto LG[2], Grasso MF[1], Feola M[3].

[1]Department of Neurology, “Regina Montis Regalis” Hospital ASLCN1- Mondovì (CN)

[2]Department of Neurology,- Civil Hospital ASL TO 4 - Ivrea (TO)

[3]Department of Cardiology, “Regina Montis Regalis” Hospital ASLCN1 - Mondovì (CN)

Background

Hereditary Transthyretin (TTR) Amyloidosis (ATTRv) is a heterogeneous disease with a clinical presentation that varies according to geographical area and TTR mutation (1). ATTRv is characterized by deposition of amyloid fibrills derived from accumulation of unstable TTR protein. The symptoms of Val50Met-ATTRv mutation are mainly neuropathic and progress to disability and death in most untreated patients within 15 years from diagnosis. The neurological signs and symptoms may also be associated with involvement of gastrointestinal system, heart, kidney and/or eyes. We report the case of a patient with ATTRv Val50Met mutation with an atypical initial presentation characterized by isolated cardiomyopathy.

Case report

A 65-year-old man, born di Piemonte (Italy) came to our attention after 2 years of exertional dyspnea. Family history was negative for neuromuscular and cardiological diseases. He had been previously diagnosed with hypertrophic cardiomyopathy (figure 1) with Cardiac T1 Mapping and Extracellular Volume (figure 2 and table) and (99 m) Tc-DPD scintigraphy (Perugini 3) compatible with cardiac amyloidosis. At the first evaluation, the patient did not show any symptoms suggestive of dysautonomia and peripheral neuropathy. His neurological examination showed isolated bilateral areflexia of achilles deep tendon reflexes. Nerve conduction studies, sympathetic skin response test, blood pressure monitoring and heart rate variability, haematological examinations were all normal. Due to endemic ATTRv in Piemonte, our team performed TTR genetic analysis. Surprisingly, the patient carried Val50Met mutation. After 6 months, the patient was clinically viewed again to monitor the neurological case. In this span of time, he began symptomatic for impotentia erigendi, and neurological examination showed reduced temperature sensation and nocturnal muscle cramps at lower limbs. Then we performed new neurophysiological examination which showed isolated bilateral pathological H reflex.

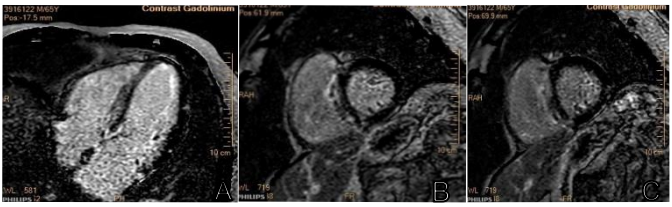

3916122 M/65Y	T1 Native: Regional Result-901, Slice No.: 1						Zoom 1.00
18 Dec, 2024 7:59:10	Segment 1	Segment 2	Segment 3	Segment 4	Segment 5	Segment 6	Summary
T1 Native	1133±65...	1172±70...	1095±53...	1064±73...	946±119...	947±162...	1078±131...
R1 Native	0.89±0.05...	0.86±0.05...	0.92±0.05...	0.94±0.06...	1.07±0.13...	1.09±0.21...	0.94±0.14...
T1 Enhanced	369±15.9...	360±13.8...	368±26.3...	378±18.6...	384±18.1...	385±33.9...	373±24.6...
R1 Enhanced	2.72±0.12...	2.78±0.10...	2.73±0.20...	2.65±0.13...	2.61±0.12...	2.61±0.23...	2.69±0.17...
ε	45.4 %	47.7 %	44.6 %	42.3 %	38.4 %	38.2 %	43.5 %
ROI Area Native	205 mm²	295 mm²	135 mm²	103 mm²	124 mm²	169 mm²	1030 mm²
ROI Area Enhanced	154 mm²	209 mm²	201 mm²	121 mm²	128 mm²	184 mm²	996 mm²
Hematocrit	42.0 %	42.0 %	42.0 %	42.0 %	42.0 %	42.0 %	42.0 %
Field Strength	1.5 T	1.5 T	1.5 T	1.5 T	1.5 T	1.5 T	1.5 T

Figure 1 (A-B-C.) The Contrast gadolinium images demonstrated areas of Late Gadolinium Enhancement (LGE) in inferior-septal wall with a non-coronary distribution (mid-wall).

Figure 2 (D-E-F). T1 mapping images that evidenced the prolonged T1 (the normal T1 mapping in our Laboratory is 990±42 ms) and prolonged Extracellular Volume (ECV normal values 26±3 %).

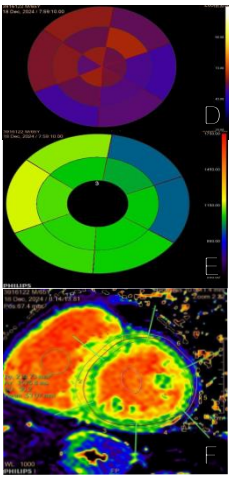

Conclusion

ATTRv is a rare and clinically heterogeneous disease. Val50Met-ATTRv mutation is the most common mutation associated with predominant peripheral and autonomic neuropathy (2). The patient we studied represents the first case with Val50Met-ATTRv mutation and predominant cardiac involvement without significant peripheral and autonomic neuropathy as initial presenting symptoms. This condition confirms the heterogeneity in the genotype–phenotype correlation of ATTRv and suggests that probably other factors may interact with disease causing mutations. Moreover, this case stresses the importance of a multidisciplinary assessment by different specialties for patients with suspected ATTRv related cardiomyopathy.

References

Connor LH, Lim A, Prokaeva T et al. Tabulation of human transthyretin (TTR) variant. Amyloid Int J exp Clin Investig Off J Int Soc Amyloidosis. 2003; 10(3): 160-84.

Alvarez Rubio J, Manovel Sanchez AJ, Gonzalez-Costello J et al. Characterization of hereditary transthyretin cardiac amyloidosis in Spain. Rev Esp Cardiol. 2022;75(6):488–495.

24-28 Ottobre 2025
Padova Congress
55° CONGRESSO SOCIETÀ ITALIANA DI NEUROLOGIA