

# A spontaneous internal carotid artery dissection in a patient with TEK-associated multiple venous malformations: risk factor or incidental finding?

Anselmi M.<sup>1</sup>, Caumo L.<sup>1</sup>, Bignamini V.<sup>1</sup>, Gaiani A.<sup>1</sup>, Piffer S.<sup>1</sup>, Palmerini F.<sup>2</sup>, Spinelli E.<sup>3</sup>, Giometto B.<sup>1</sup>

<sup>1</sup>U.O. Neurologia - Ospedale S. Chiara - Trento;

<sup>2</sup>U.O. Neurologia - Fondazione Poliambulanza - Brescia;

<sup>3</sup>U.O. Oncologia - Fondazione Poliambulanza - Brescia

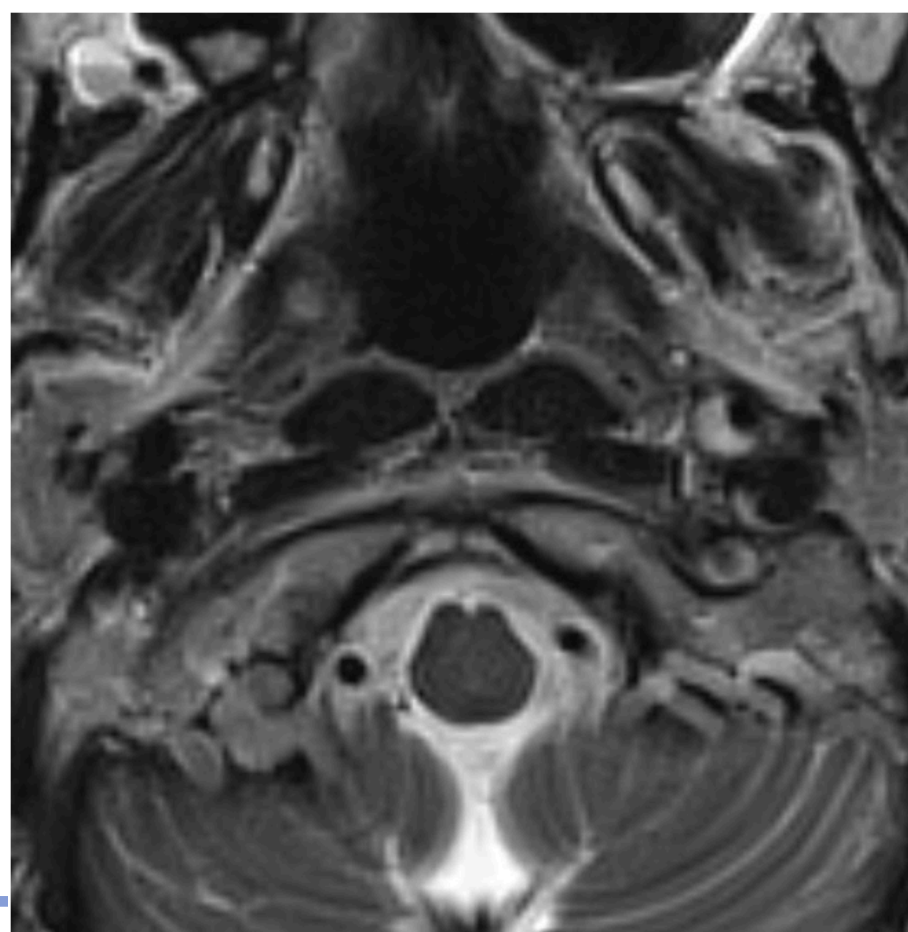


## Introduction

*TEK/TIE-2* gene encodes a tyrosine kinase receptor for angiotensin, expressed by endothelial cells. *TEK* regulates angiogenesis, endothelial cell homeostasis promoting stability and regulating permeability in quiescent vessels. Unsurprisingly, heterozygous *TEK* mutations lead to the formation of abnormal blood vessels, and are associated with congenital glaucoma and venous malformation (VM) syndrome encompassing common unifocal or multifocal VM, multiple mucocutaneous VM, blue rubber bleb nevus or hemangioma.<sup>1</sup> We describe a patient with *TEK*-associated multiple mucocutaneous VM associated with non traumatic spontaneous distal extracranial internal carotid artery dissection.

## Methods

- 51-years-old female with:
- History of hypertension and a hospitalization for tachycardia with elevated cardiac enzymes, discovering congenital left ventricular diverticulum.
- Multiple angioma-like lesions in the neck, face, brain and arms, like her mother and her maternal grandmother.
- For subjective vertigo and pulsating tinnitus performed neck and brain MRI with angiography showing crescent moon-shape of cervical distal tract and a thinning of the proximal petrous tract of the left internal carotid artery, small right parietal developmental venous malformation and multiple hemangiomas in the parotid gland and neck muscles.



T2- weight sequence of brain MRI, showing typical “crescent moon” appearance suggestive for dissection in the left distal extracranial carotid artery.

## Results

- Neurological examination: unremarkable.
- Blood tests: mild hypercholesterolemia.
- CT angiography of abdomen and chest excluded other dissections-vascular malformations.
- Follow-up CT angiography and brain MRI at 18 months: partial recanalization of the carotid artery, with a residual stenosis in the intracavernous tract.
- Exome sequencing: novel heterozygous *TEK* mutation c.3301-2A>G, located in a splice acceptor site. Classified as “likely pathogenic” according to ACMG criteria.

## Conclusions

To our knowledge, this is the first reported case of spontaneous carotid artery dissection occurring in a patient with a *TEK*-associated multiple mucocutaneous VM syndrome. Given the important role of the *TEK/TIE2* gene in endothelial homeostasis and its involvement in atherosclerosis development<sup>2</sup> as well as in aortic dissection<sup>3</sup> through modulation of vascular permeability and inflammatory responses, we speculate that genetic variants in this gene may increase susceptibility to cervical artery dissection. Further studies are needed to clarify the precise causal relationship.

### References

1. Seront E. et al. “TEK-Related Venous Malformations”, 2008
2. Anisimov A. et al. “The angiotensin receptor Tie2 is atheroprotective in arterial endothelium”, 2023
3. Zheng L et al. “Identification of Key Immune Infiltration Related Genes Involved in Aortic Dissection Using Bioinformatic Analyses and Experimental Verification”, 2024



24-28 Ottobre 2025  
Padova Congress

55° CONGRESSO  
SOCIETÀ ITALIANA  
DI NEUROLOGIA